

# A study to analyze the prevalence of nervous anastomosis (Martin-Gruber) in medical students

Nilesh N Kate<sup>1</sup>, Chandrika G Teli<sup>2</sup>, Ratnesh Gajbhiye<sup>1</sup>, Kondam Ambareesha<sup>3</sup>, M Suresh<sup>3</sup>

<sup>1</sup>Department of Physiology, ESIC Medical College and Hospital, Gulbarga, Karnataka, India.

<sup>2</sup>Department of Anatomy, ESIC Medical College and Hospital, Gulbarga, Karnataka, India.

<sup>3</sup>Department of Physiology, Meenakshi Medical College & RI, Enathur, Kanchipuram, Tamil Nadu, India.

Correspondence to: Nilesh N. Kate, E-mail: [nileshkate79@gmail.com](mailto:nileshkate79@gmail.com)

Received July 12, 2014. Accepted December 9, 2014

## ABSTRACT

**Background:** In nerve conduction laboratory, various types of cases are encountered. These are generally referred for electrophysiological investigation of the most common syndromes such as carpal tunnel syndrome where there is partial or total sparing of the thenar muscles from the effect of compression of their nerve supply. So for the assessment of traumatic and entrapment lesions of median and ulnar nerves, the knowledge of these anastomosis is important. **Aims and Objectives:** The purpose of this study was to assess the prevalence of this anastomosis in healthy individuals, to draw attention of clinicians or surgeons from neurophysiology field to this anastomosis, and to avoid misinterpretations of different studies of needle electromyography and other nerve conduction studies. **Materials and Methods:** A total of 150 healthy volunteers were selected from the medical students aged 17–30 years. Surface recording electrodes were placed on the hand abductor pollicis brevis, abductor digiti minimi, and the first dorsal interossei (FDI) of each subject. Using surface electrodes, we percutaneously stimulated the median and ulnar nerves at the wrist and the elbow. Rectangular pulses of 0.2 ms duration were used and the stimulus strength was supramaximal. Compound muscle action potential (CMAP) was recorded. CMAP from the FDI, hypothenar, and thenar muscles larger (at least 1.0 mV) on median nerve stimulation at the elbow than at the wrist and that from one or more of these sites larger (at least 1.0 mV) on stimulation of ulnar nerve at the wrist than at the elbow were accepted as indicators of the presence of the MGA. Analysis was carried out using Statistical Package for Social Sciences, version 10.0. *P*-value < 0.05 was considered as statistically significant. **Results:** The type of anastomosis frequently observed was type II, which was observed in 12 subjects; type I was observed in 3; type I + II was observed in 2; and type III was observed in 1 subject. **Conclusion:** Because of its high incidence and different electrodiagnostic considerations, MGA should be considered to be of great clinical significance for correct diagnosis and for planning appropriate therapy in peripheral lesions of median and ulnar nerves.

**KEY WORDS:** Compound Muscle Action Potential; Median Nerve; Ulnar Nerve; Martin-Gruber Anastomosis

### Access this article online

Website: <http://www.njppp.com>

DOI: 10.5455/njppp.2015.5.1207201414

Quick Response Code:



## INTRODUCTION

Most fascinating and most complex aspects of surgeries of hands include compressive neuropathy. It is the most rewarding surgery in terms of clinical outcomes with some exceptions.

During the diagnosis of cases such as carpal tunnel syndrome (CTS) by electrophysiological investigation in nerve conduction laboratory, some cases were encountered where there was

National Journal of Physiology, Pharmacy and Pharmacology Online 2015. © 2015 Nilesh N. Kate. This is an Open Access article distributed under the terms of the Creative Commons Attribution 4.0 International License (<http://creativecommons.org/licenses/by/4.0/>), allowing third parties to copy and redistribute the material in any medium or format and to remix, transform, and build upon the material for any purpose, even commercially, provided the original work is properly cited and states its license.

partial or total sparing of muscles from the effect of compression of the corresponding nerve supply. In another case of ulnar nerve lesion, one could not find any denervation in hypothenar muscles. These abnormal findings can be explained by the presence of an abnormal anastomosis of nerves in the upper extremity.

One of the most important anastomoses of nerves in the upper extremity is Martin-Gruber anastomosis (MGA). In this, there are crossovers of nerve fibers in the forearm between median and ulnar nerves. Communication between the median and ulnar nerves in the hand and in the forearm shows variations in the innervations of the intrinsic hand muscles, as proved by anatomical and nerve conduction studies.<sup>[1]</sup> Most of the connections cross from the median nerve to the ulnar nerve and are bilateral in 10%–40% of the cases. This anomaly was first described by the Swedish anatomist R. Martin in 1763 and later by Gruber in 1870 and is thus referred to as the Martin-Gruber anastomosis (MGA). The axons in this anastomosis may innervate any of the intrinsic hand muscles, most commonly the FDI.<sup>[2,3]</sup>

Various forms and connections were found in Martin's cadaver dissections.<sup>[4]</sup> This anastomosis involves axons leaving either the main trunk of median nerve or the anterior interosseous nerve, crossing through the forearm to join the main trunk of the ulnar nerve and ultimately innervating the intrinsic hand muscles.<sup>[5]</sup>

MGA may lead to misdiagnosis of conditions affecting the nerve supply to the upper extremity, particularly intrinsic muscles of hand. So for the assessment of traumatic and entrapment lesions of median and ulnar nerves, it is important to have the knowledge of these anastomoses.

Its reported incidence differs between physiologic and anatomic studies. In the former it has been described as occurring in 5–40% of cases<sup>[6–8]</sup> whereas anatomic studies report a narrower range of 10–30.6%.<sup>[9–13]</sup> In the literature, on human fetuses (normal and congenitally abnormal fetuses) there was only one study<sup>[14]</sup> that reported the incidence of MGA (15%).

The purpose of this study was to determine the prevalence of MGA in a sample of medical students and to draw the attention of the neurologist and specially hand surgeons to the possible presence of this anastomosis in general population. So, the misinterpretations of different studies of needle electromyography (EMG) and other nerve conduction studies can be avoided. This knowledge will be of great help in the assessment of traumatic and entrapment lesions of median and ulnar nerves.

### Lacunae

Though their occurrence is frequent, lacunae have received very little attention in Indian population. In our laboratory, it is viewed as an important additional criterion to explain the occurrence of unusual findings in the lesions of the nerves in the upper extremity and other electrophysiological studies.

### Objective

The aim of the present study was to analyze the prevalence of nervous anastomosis (Martin-Gruber) in medical students.

## MATERIALS AND METHODS

This cross-sectional study was conducted in the Department of Physiology, Meenakshi Medical College and Research Institute, Kancheepuram. A total of 150 apparently healthy subjects of either sex (60 males and 90 females) aged 17–30 years were selected after taking of their informed written consent. Individuals having or reported a history of neuropathy, limb injury or ulcer, neuromuscular transmission disorder, myopathy, and alcohol abuse were excluded from the study.

All participants were examined to exclude history of systemic or neuromuscular disorder. Relevant clinical history was taken and neurological examination was carried out. An approval from institutional ethics committee was obtained, and the study was carried out at a fixed room temperature of 30°C.

### Electrophysiological Methods

An RMS EMG EP Mark-II machine was used. Filters were set at 2 Hz–5 kHz, sweep speed was 5 ms per division, and duration was at 100  $\mu$ s. Ulnar nerve motor conduction studies were performed in conventional way. The sites of stimulation were the wrist and elbow, and recording sites were motor point of abductor digiti minimi and first dorsal interosseus (FDI). Reference electrode was placed 3–4 cm distal to active electrode.

Belly-tendon montage was used with cathode and anode 3 cm apart. Care was taken to limit the supramaximal nerve stimulation to the nerve being studied. Whenever there was more than 10% drop in the compound muscle action potential (CMAP) amplitude between the wrist and below-elbow sites on routine ulnar motor study, median nerve was stimulated at wrist and at antecubital fossa while active electrode on abductor digiti minimi and FDI. Ground electrode was placed between stimulation and recording electrodes.<sup>[6]</sup> The diagnosis of MGA was made on the basis of amplitude of CMAP increase after median nerve stimulation at antecubital fossa as compared to stimulation at wrist. The corresponding decrease in CMAP amplitude was found after below-elbow stimulation as compared with the wrist stimulation in ulnar nerve conduction studies.<sup>[7]</sup>

### Statistical Analysis

Analysis was carried out using Statistical Package for Social Sciences, version 10.0. *P*-value <0.05 was considered as statistically significant.

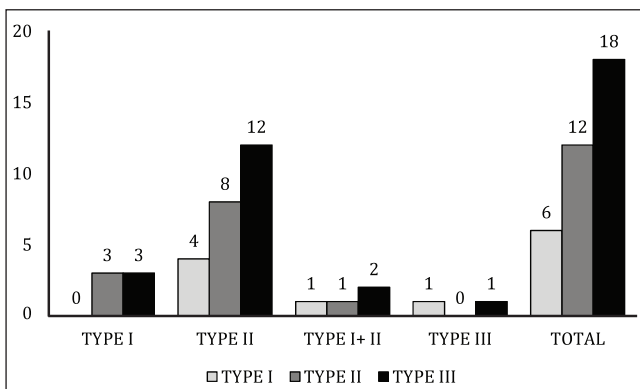
## RESULTS

MGAs were found in 18 of the 150 persons tested: 12 had type II, 3 had type I, 2 had type I + type II, and 1 had type III. The total number of anastomosis was 18. In the group of 90 women, 6 subjects (6.67%) were found to have MGA. Four women (4.45%) had type II, one (1.12%) had type I + type II,

**Table 1:** Distribution of Martin-Gruber anastomosis in the studied subjects

	Type I		Type II		Type I + II		Type III		Total	
	n	%	n	%	n	%	n	%	n	%
F (90)	0	0	4	4.45	1	1.12	1	1.12	6	6.67
M (60)	3	5	8	13.34	1	1.67	0	0	12	20
F + M (150)	3	2	12	8	2	1.34	1	0.67	18	12

F, female; M, male

**Graph 1:** Graphical distribution of Martin-Gruber anastomosis in the studied subjects.

and one (1.12%) had type III MGA. Of the 60 male subjects, 12 (20%) had MGA. Eight (13.34%) cases had MGA type II, three (5%) had MGA type I, and one (1.67 %) had type I + type II. Table I shows the number of men and women with different types and combinations of MGAs. Graph 1 shows the distribution of MGA in the studied subjects.

## DISCUSSION

### Martin-Gruber Communications

There are many anatomical variations in and around the carpal tunnel that affect the nerves, tendons, and arteries in this area. Awareness of these variations is important both during the clinical examination and during carpal tunnel release. The presence of symptoms that do not follow the classical distribution of the median and ulnar nerves in the hand should lead one to consider the presence of an MGA or Marinacci communication. A mass or lump detected within the transverse carpal ligament should be examined with gliding of the fingers, as it may represent a proximal origin of the index lumbrical, or an anomalous muscle belly of the FDI to the indicis.

MGAs most commonly innervate the FDI and the hypothenar muscles.<sup>[17-19]</sup>

The anatomical study of muscles supplied by the ulnar and median nerves is clinically important for understanding the

mechanism of lesions. MGAs have been misdiagnosis during the assessment of nerve injuries,<sup>[20]</sup> carpal tunnel syndrome,<sup>[21]</sup> cubital tunnel syndrome,<sup>[18]</sup> and leprosy neuropathy.<sup>[15]</sup>

The presence of MGA is the source of diagnostic difficulty in the cases of CTS. Normal motor latencies are obtained in such cases. However, there are certain clues to the correct diagnosis:

1. Median nerve stimulation at the elbow evokes a thenar CMAP with initial positive deflection not seen on stimulation at the wrist.<sup>[21]</sup>
2. A thenar CMAP with two peaks in the negative phase is seen upon median nerve stimulation at the elbow.<sup>[22]</sup>
3. An erroneously normal proximal (elbow) motor latency in the median nerve with prolongation of the distal motor latency results in a spuriously fast conduction velocity by calculation.<sup>[23,24]</sup>

The incidence of MGAs in the present study was found to be 12%, compared to previously reported frequencies of 10.5%–23%.<sup>[10,25-30]</sup>

The type of anastomosis frequently seen was type II, which was observed in 12 subjects; type I was observed in 3; type I + II was observed in 2; and type III was observed in 1 subject. An anomalous connection, commonly known as an MGA, may occur between the median and ulnar nerves in the forearm, resulting in varied patterns of innervations to the intrinsic muscles of the hand.<sup>[3,9,10,12,15,31,32]</sup> The MGA is median-to-ulnar in nature.<sup>[8]</sup> It has been reported to affect 6%–31% of the population.<sup>[22]</sup> The Marinacci communication, also known as a reverse MGA, is a rare condition in which the communicating nerve fibers run from the ulnar nerve to the median nerve. In a case report by Stancic et al.,<sup>[33]</sup> this connection was identified in the distal forearm during release of the carpal tunnel via an extended incision. To date, there have been only four published cases of Marinacci communication.<sup>[33-36]</sup>

In relations to the type of nerve fibers involved, Hasegawa et al.<sup>[37]</sup> described MGAs as a motor anastomosis that spreads from the median to the ulnar nerves in the forearm, whereas Simonetti<sup>[38]</sup> stated that the anastomosis also involved sensory fibers moving in the opposite direction (ulnar-to-median nerves).

Despite the lower frequency of MGAs, these anastomoses are still important when diagnosing nerve injuries. No

important gender and racial differences were found in this study with regard to the incidence of MGAs. In an electrodiagnostic study of 1200 forearms in Japanese volunteers, Kayamori<sup>[39]</sup> found an MGA incidence of 9.7% and no significant difference between males and females. However, some reports have suggested a relationship between genetic factors and the presence of MGA. Crutchfield and Guttmann<sup>[7]</sup> reported a study of MGA in five subjects from the same family. Srinivasan and Rhodes<sup>[14]</sup> examined congenitally abnormal fetuses and found that all fetuses with trisomy 21 had an MGA in both forearms. These findings suggested an autosomal dominant inheritance. Leibovic and Hastings<sup>[31]</sup> have proposed a comprehensive classification for MGAs that includes ulnar-to-median connections. The rarity of these anastomoses indicates that they are anomalies.

Kimura et al.<sup>[40]</sup> stated that no ulnar-to-median anastomoses were observed electrophysiologically in any of the 656 hands that they examined. Similarly, Wilbourn and Lambert<sup>[19]</sup> found no such connections in 200 forearms. Nakashima<sup>[9]</sup> dissected 108 forearms and found only median-to-ulnar connections, which were present in 21% of the cases.

During carpal tunnel surgery, attention to anatomical variations is of obvious importance, particularly with respect to the palmar cutaneous nerve and the recurrent branch of the median nerve. Interestingly, considering the incidence of such variations, not many related complications have been reported during endoscopic carpal tunnel release, where many of the variations cannot be seen intraoperatively. Regardless of the approach to carpal tunnel release, it is imperative that plastic surgeons be cognizant of these variations and be vigilant during carpal tunnel release.

Despite the low incidence of MGAs observed here, the importance of an adequate investigation of these connections needs to be underscored. Understanding the existence of this variation, its location, and its possible presentation is important for correct patient assistance.

## CONCLUSION

Because of its high incidence and different electrodiagnostic considerations, MGA should be considered to be of great clinical significance for correct diagnosis and for planning appropriate therapy in peripheral lesions of median and ulnar nerves.

## REFERENCES

- Oh SJ. Clinical *Electromyography. Nerve Conduction Studies*. Baltimore, MD: Lippincott Williams & Wilkins, 1993. pp. 314–33.
- Guttmann L. AAEM minimonograph #2: important anomalous innervations of the extremities. *Muscle Nerve*. 1993;16:339–47.
- Uchida Y, Sugioka Y. Electrodiagnosis of Martin-Gruber connection and its clinical importance in peripheral nerve surgery. *J Hand Surg*. 1992;17A:54–9.
- Sarikcioglu L, Demirel BM. Martin-Gruber and Marinacci communications—anatomic or physiologic consideration. *J Hist Neurosci*. 2006;15:99–101.
- Erdem HR, Ergun S, Erturk C, Ozel S. Electrophysiological evaluation of the incidence of Martin-Gruber anastomosis in healthy subjects. *Yonsei Med J*. 2002;43:291–5.
- Sarikcioglu L, Sindel M, Ozkaynak S, Aydin H. Median and ulnar nerve communication in the forearm: a anatomical and electrophysiological study. *Med Sci Monit*. 2003;9:351–6.
- Crutchfield CA, Guttmann L. Hereditary aspects of median-ulnar nerve communications. *J Neurol Neurosurg Psychiatry*. 1980;43:53–5.
- Lee KS, Oh CS, Chung IH, Sunwoo IN. An anatomic study of the Martin-Gruber anastomosis: electrodiagnostic implications. *Muscle Nerve*. 2005;31:95–7.
- Nakashima T. An anatomical study on the Martin-Gruber anastomosis. *Surg Radiol Anat*. 1993;15:193–5.
- Taams KO. Martin Gruber connections in South Africa. *J Hand Surg*. 1997;22B:328–30.
- Kawashima T, Sato K, Sasaki H. Stratification of the flexor retinaculum and the course and distribution of the ulnar, median and palmar digital nerves: an anatomical study. *Clin Anat*. 2004;17:643–50.
- Shu HS, Chantelot C, Oberlin C, Alnot JY, Shao H. Martin-Gruber communicating branch: anatomical and histological study. *Surg Radiol Anat*. 1999;21:115–18.
- Rodriguez-Niedenfuhr M, Vazquez T, Parkin I, Logan B, Sanudo JR. Martin-Gruber anastomosis revisited. *Clin Anat*. 2002;15:129–34.
- Srinivasan R, Rhodes J. The median-ulnar anastomosis (Martin-Gruber) in normal and congenitally abnormal fetuses. *Arch Neurol*. 1981;38:418–19.
- Brandsma JW, Birke JA, Sims DS Jr. The Martin-Gruber innervated hand. *J Hand Surg [Am]*. 1986;11:536–9.
- Rodriguez-Niedenfuhr M, Vazquez T, Ferreira B, Parkin I, Nearn L, Sanudo JR. Intramuscular Martin-Gruber anastomosis. *Clin Anat*. 2002;15:135–8.
- Amoiridis G. Median-ulnar nerve communications and anomalous innervation of the intrinsic hand muscles: an electrophysiological study. *Muscle Nerve*. 1992;15:576–9.
- Uchida Y, Sugioka Y. Electrodiagnosis of Martin-Gruber anastomosis. *J Hand Surg*. 1992;17:47–53.
- Wilbourn AJ, Lambert EH. The forearm median-to-ulnar nerve communication: electrodiagnostic aspects. *Neurology*. 1976;26:368.
- Van Tieghen J, Vandendriessche G, Vanhecke J. Martin-Gruber anastomosis: the explanation for late diagnosis of severe ulnar nerve lesions at the elbow. *Electromyogr. Clin Neurophysiol*. 1987;27:13–18.
- Guttmann L. Median-ulnar nerve communications and carpal tunnel syndrome. *J Neurol Neurosurg Psychiatry*. 1977;40:982–6.
- Lambert EH. Diagnostic value of electrical stimulation of motor nerves. *EEG Clinical neurophysiology*. 1962;22(Suppl):9–16.
- Iyer V, Fenichel GM. Normal median nerve proximal latency in carpal tunnel syndrome: a clue to coexisting Martin-Gruber anastomosis. *J Neurol Neurosurg Psychiatry*. 1976;39:449–52.
- Kimura J. Collision technique. *Neurology*. 1976;26:680–2.
- Almeida JA, Vitti M, Garbino JA. Estudo anatômico da anastomose de Martin-Gruber. *Hansen Int*. 1999;24:15–20.
- Gruber W. Über die Verbindung des Nervus medianus mit dem Nervus ulnaris am Unterteil des Menschen und der Säugetiere. *Arch Anat Physiol*. 1870;37:501–22.
- Hirasawa K. Untersuchungen über das periphere Nervensystem, Plexus brachialis und die Nerven der oberen Extremitäten. *Arch Anat Inst Kaiserlichen*. 1931;2:135–7.
- Mannerfelt L. Studies on the hand in ulnar nerve paralysis. A clinical-experimental investigation in normal and anomalous innervation. *Acta Orthop Scand* 87(Suppl):23–6.

29. Ohkubo K, Itami Y, Murota K, Fujii K, Morita S, Kato S. Anatomical study of anastomosis between the median and ulnar nerves in the forearm (Martin-Gruber). *Orthop Surg.* 1976;27:1244-8.
30. Thomson A. Third annual report of the committee of collective investigation of the Anatomical Society of Great Britain and Ireland. *J Anat.* 1983;27:183-94.
31. Leibovic SJ, Hastings H. Martin-Gruber revisited. *J Hand Surg.* 1992;17A:47-53.
32. Simonetti S, Krarup C. Unusual ulnar sensory innervation and Martin-Gruber anastomosis in a patient with a carpal tunnel syndrome. *J Neurol.* 2000;247:141-2.
33. Stancic MF, Burgic N, Micovic V. Marinacci communication. *J Neurosurg.* 2000;92:860-2.
34. Kimura I, Ayyar DR, Lippmann SM. Electrophysiological verification of the ulnar to median nerve communications in the hand and forearm. *Tohoku J Exp Med.* 1983;141:269-74.
35. Marinacci A. The problem of unusual anomalous innervation of hand muscles: the value of electrodiagnosis in its evaluation. *Bull Los Angeles Neruol Soc.* 1964;29:133-42.
36. Streib EW. Ulnar-to-median nerve anastomosis in the forearm: electromyographic studies. *Neurology.* 1976;29:1534-7.
37. Hasegawa O, Matsumoto S, Iino M, Kirigaya N, Mimura E, Wada N, et al. [Prevalence of Martin-Gruber anastomosis on motor nerve conduction studies]. *No To Shinkei.* 2001;53:161-4.
38. Simonetti S. Electrophysiological study of forearm sensory fiber crossover in Martin-Gruber anastomosis. *Muscle Nerve.* 2001;24:380-6.
39. Kayamori R. Electrodiagnosis in Martin-Gruber anastomosis. *J Jpn Orthop Assoc.* 1987;61:1367-72.
40. Kimura J, Murphy MJ, Varda DJ. Electrophysiological study of anomalous innervation of intrinsic hand muscles. *Arch Neurol.* 1976;33:842-4.

**How to cite this article:** Kate NN, Teli CG, Gajbhiye R, Ambareesha K, Suresh M. A study to analyze the prevalence of nervous anastomosis (Martin-Gruber) in medical students. *Natl J Physiol Pharm Pharmacol* 2015;5:185-189

**Source of Support:** Nil, **Conflict of Interest:** None declared.